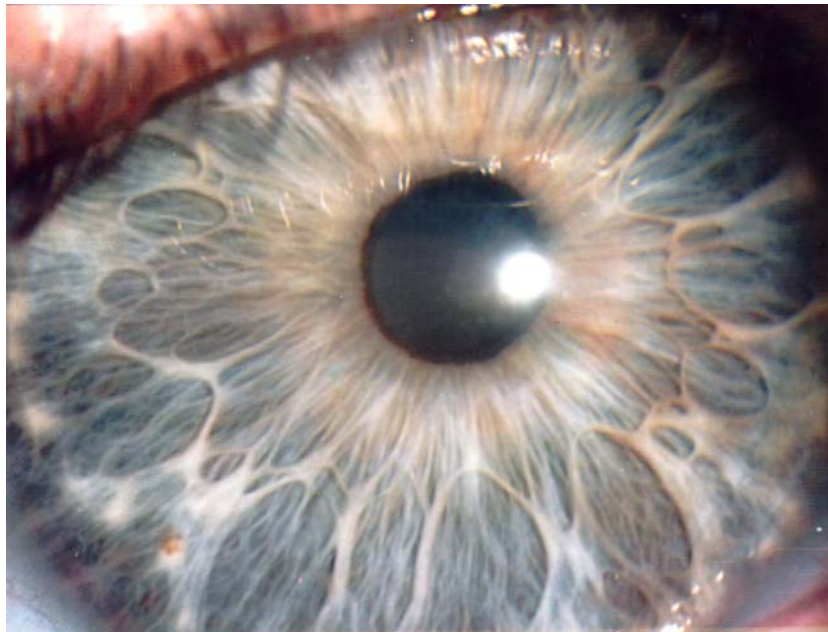
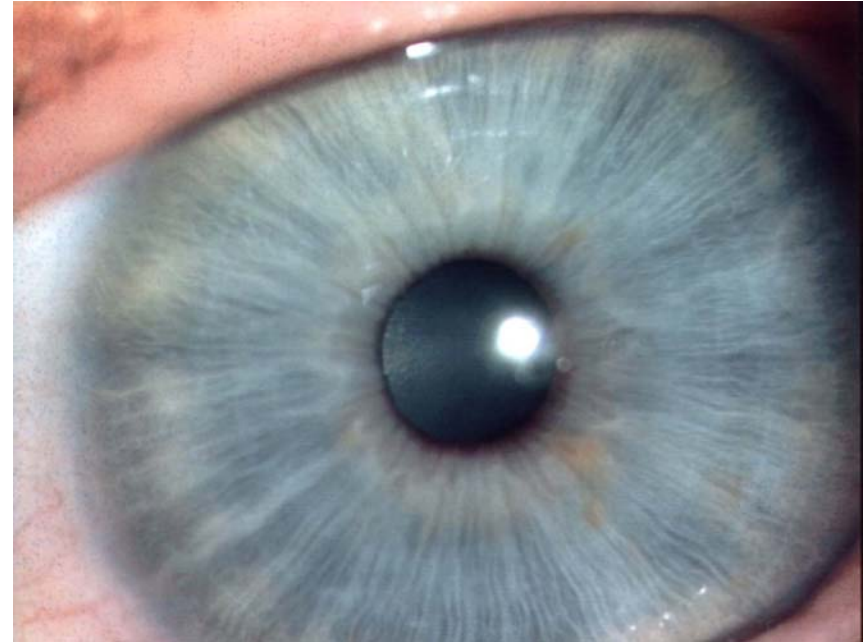


Iridology reveals a great deal about the body.

Photos extracted from my new
book on autointoxication, bowel
disease and detoxification.

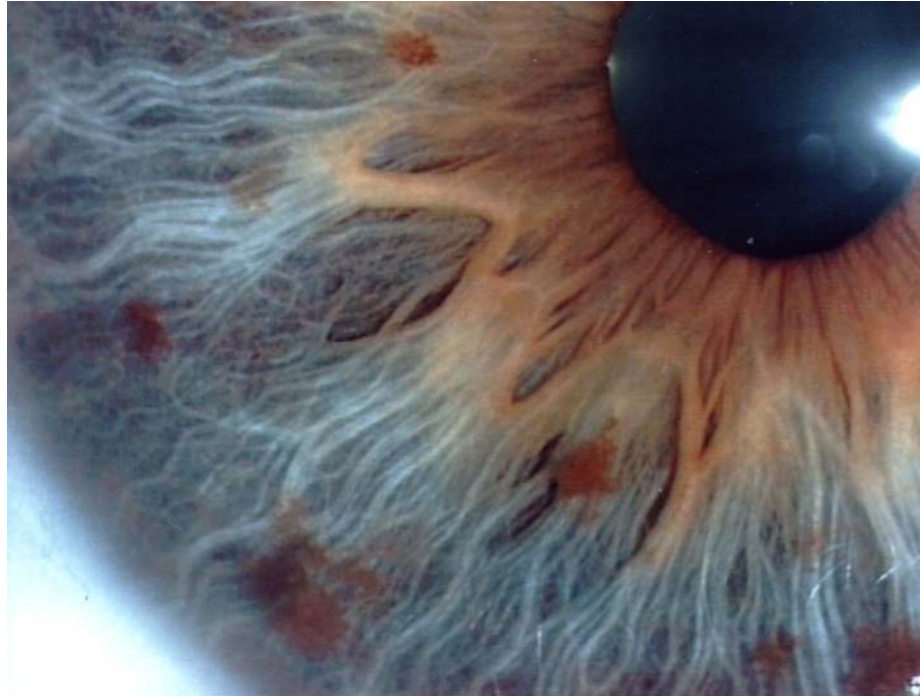
Serge Jurasunas
www.sergejurasunas.com

Typical example of a true blue iris with a good constitution, good fibers alignment, good bowel function and resistance to disease. Healthy person until old age.



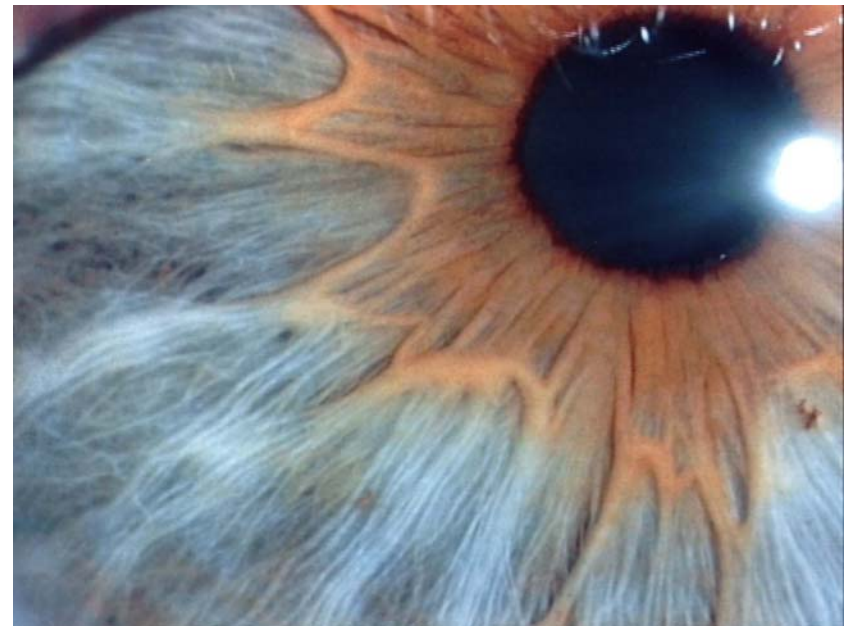L. Iris – M.26 years

Very poor constitution, exaggerated nerve wreath going to the ciliary and periphery zone of the iris. Major inflammatory process, large acute and chronic lesion. Genetic neural reflexe and brain tumor.

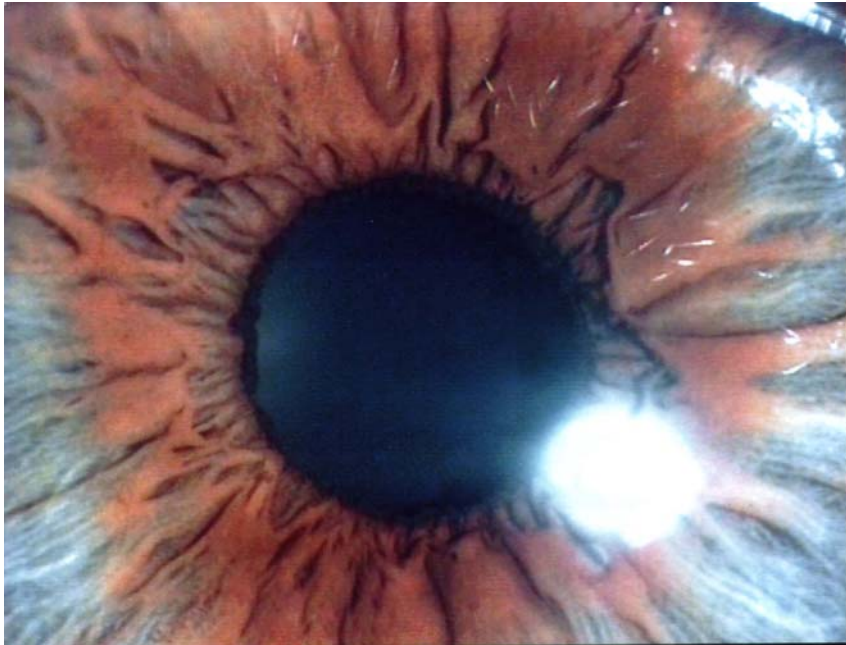


Exaggerated nerve wreath in zig zag developing reflexe tissue irritation and inflammation in various zone of the ciliary.

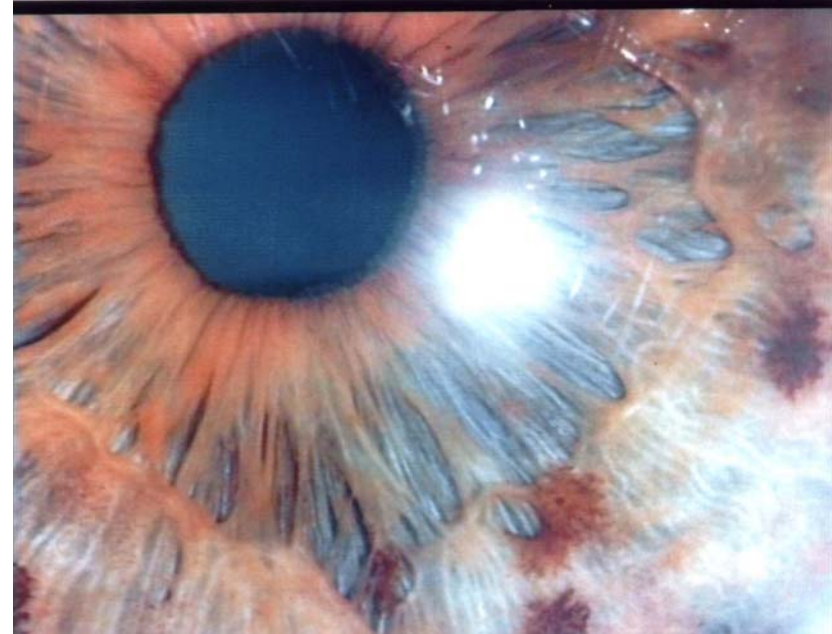
Fibers of the top layer are separate from each other and start to create lesions.



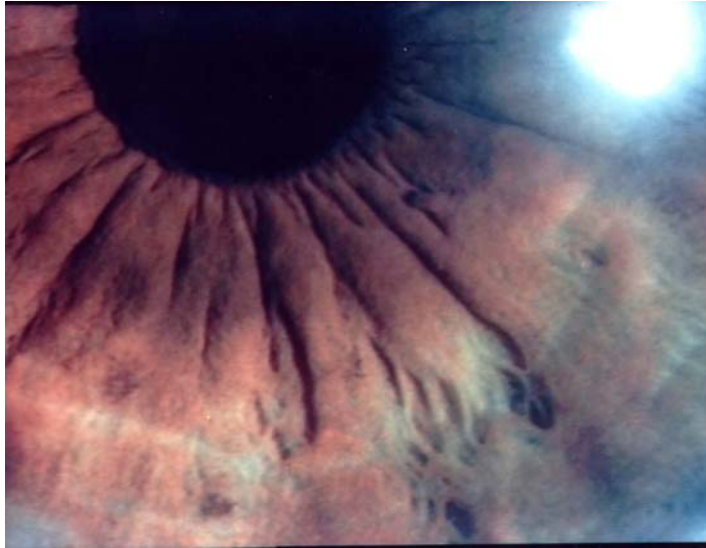
Two different bowel



Left iris – strangulated colon with nerve wreath near the pupil. By reflex affect epileptic zone 1 o'clock.



M.66 years – L.Iris – Poor constitution - balloned colon and inflammatory process – pressure on the rectum – degenerative lesion visible near 7 o'clock – Tumor of the rectum.



F.38 years – L.Iris – Ovary cancer
(5 o'clock)

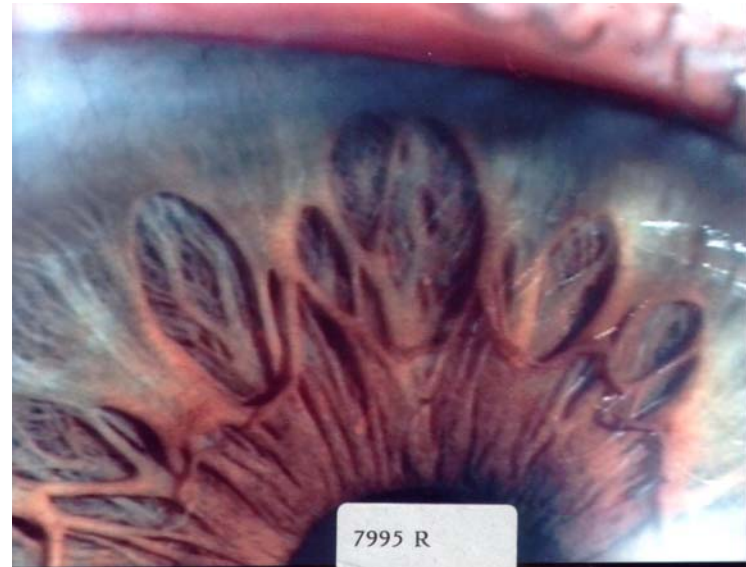Bad bowel, very toxic especially when nerve wreath is close to pupil, which reflexly affect the ovary

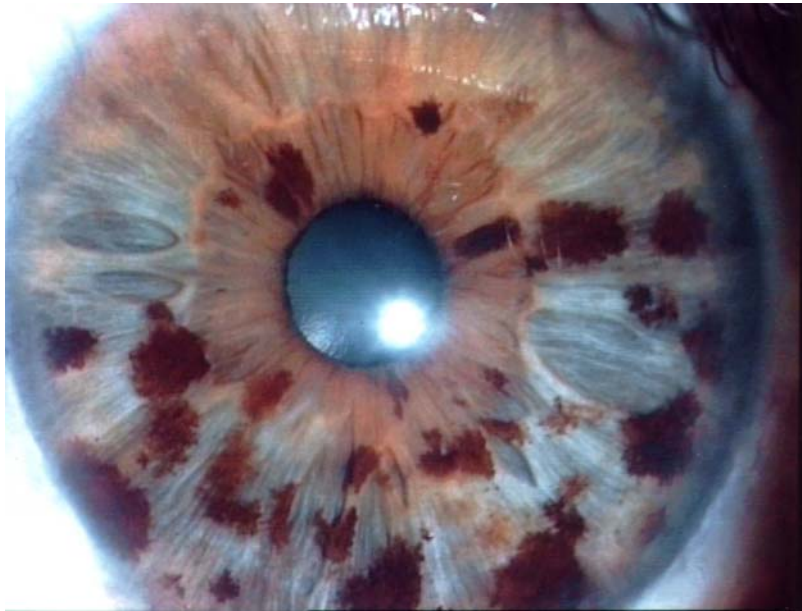
F.39 years – R.Iris – Teacher
Brain area.

Animation life center (12 o'clock) -
Hypothalamus - energy center
11.40 – Midbrain – Brain stem.

-Sensorial disorder, fatigue, melancholy,
indifference, anxiety, vertigo, lack of
coordination between brain and muscles -
Panic crises, pain in neck.

Nerve wreath in zig zag – very bad bowel
condition and constipation (one elimination
every 5 days) – brain aging





M. 56 years – L. Iris - bronchial cancer.

Inflammation between 3 and 4 o'clock.

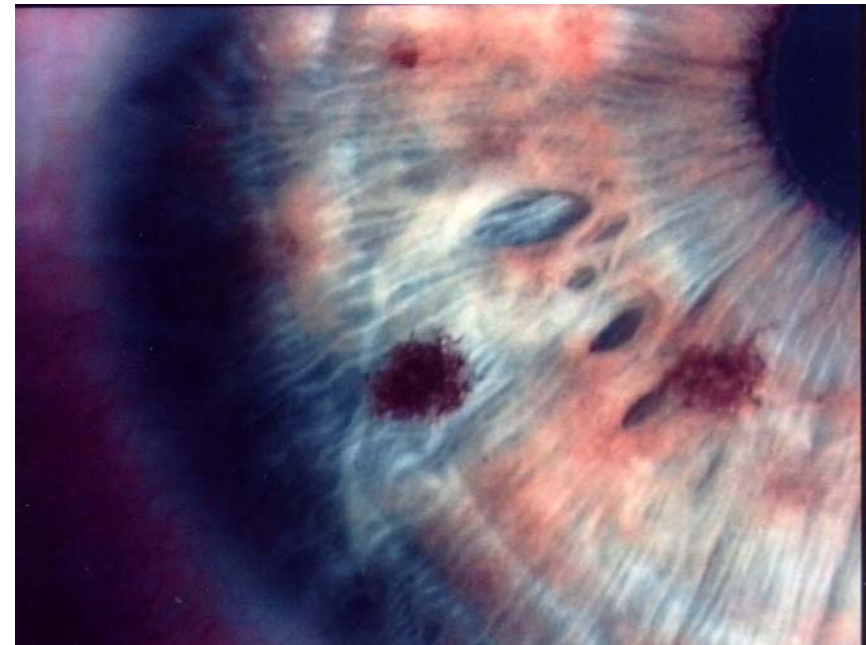
Dark and brown spots distributed all over both iris.

F. 42 years

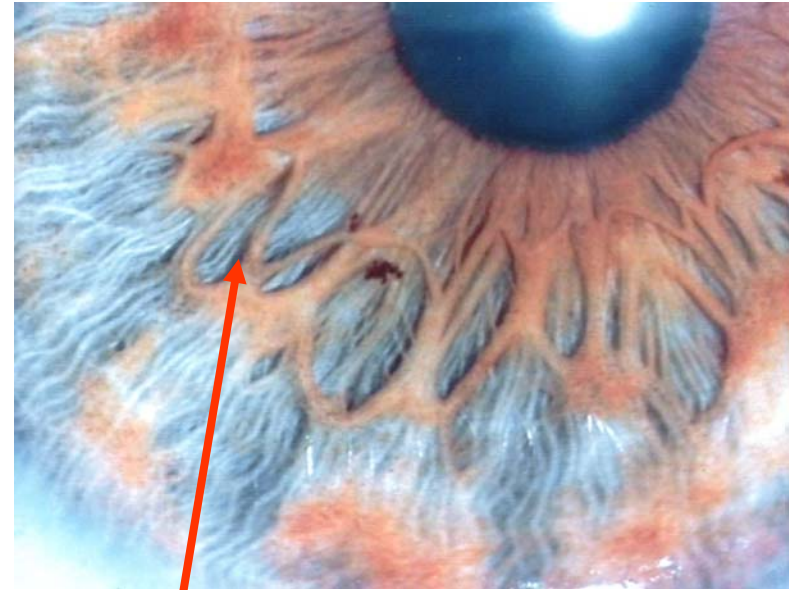
R. Iris –

Degenerative lesion visible on liver area with brown spots and transversale crossing the area.

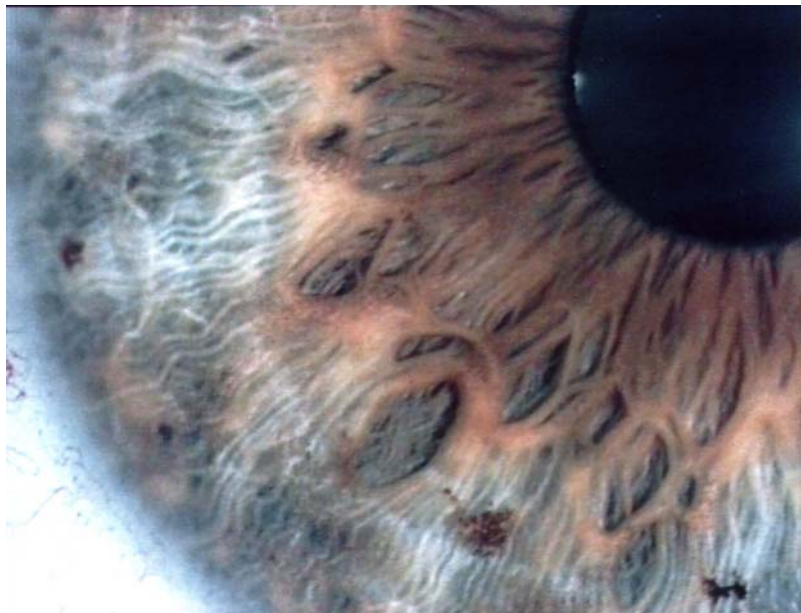Family cancer risk – liver – colon.



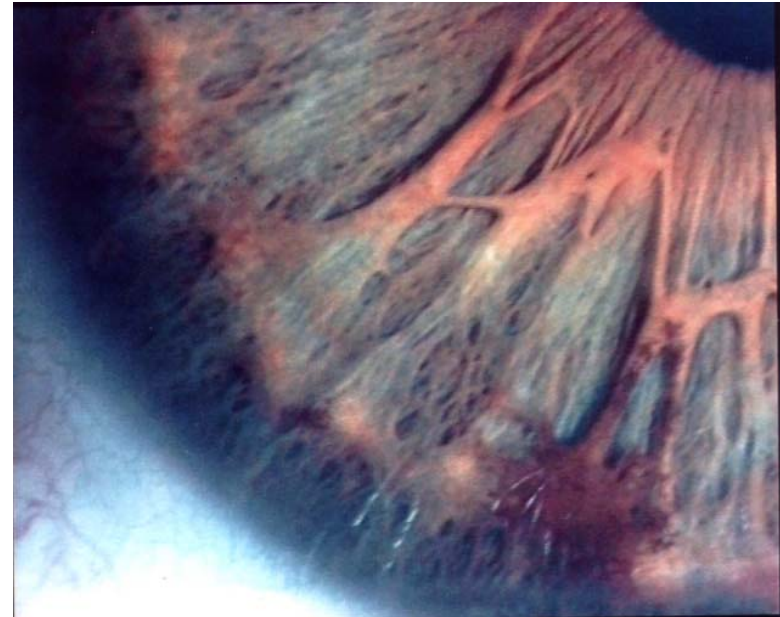
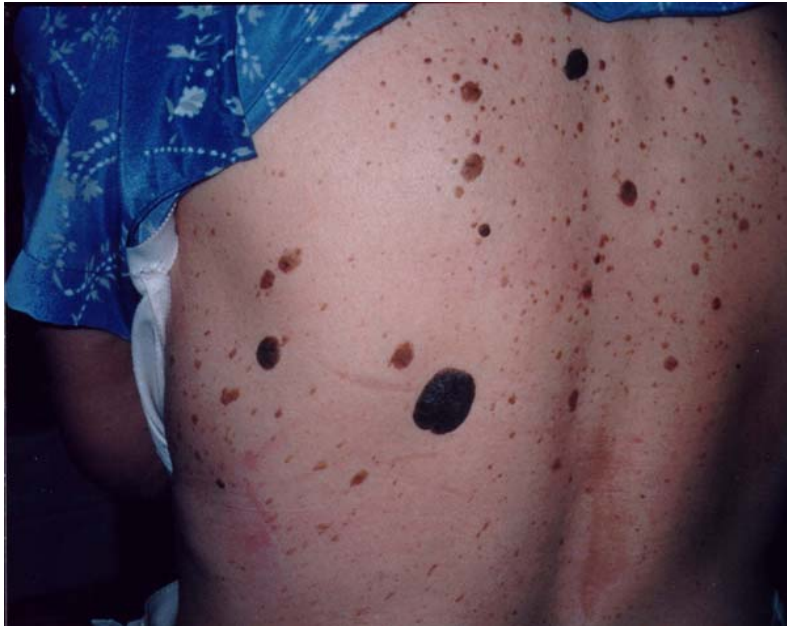F.14 years – Chronic hepatitis degeneration in cirrhosis
R.Iris – Exaggerated nerve wreath making a butterfly on liver such in neural-genetic-reflex syndrom.
Both mother and father have bad liver.



Neuro-genetic-reflex

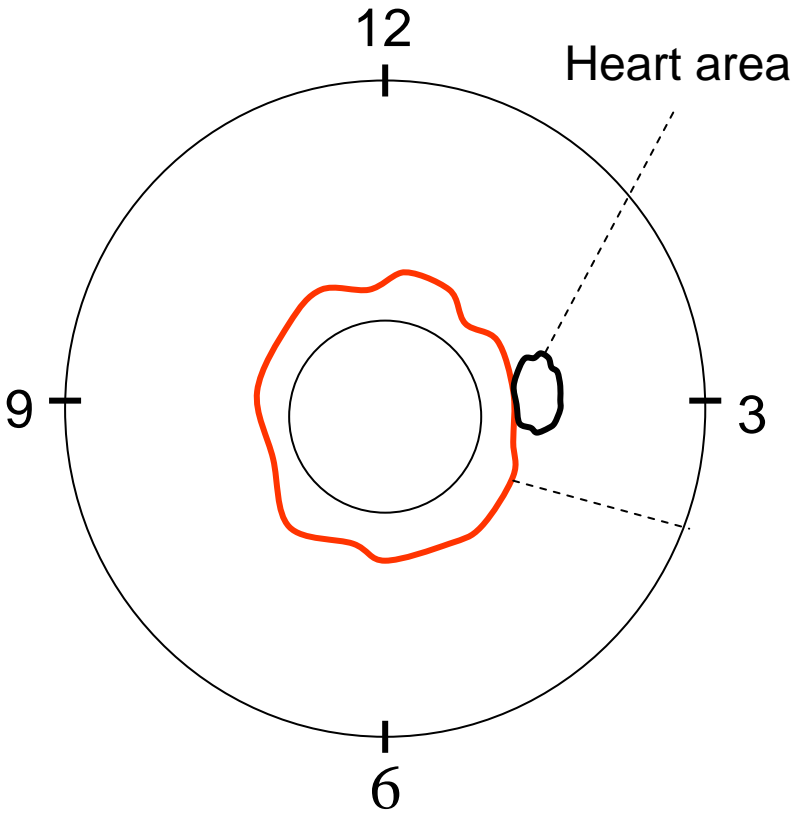
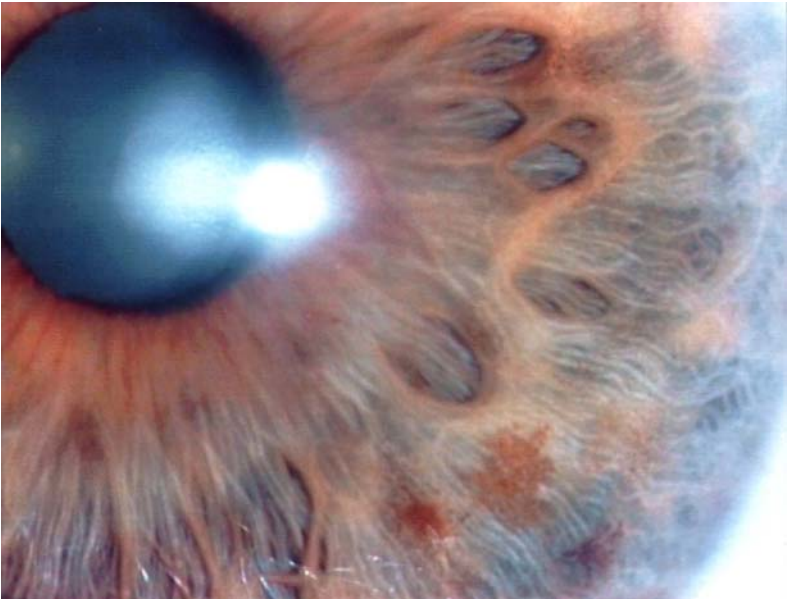


The iris of her mother.

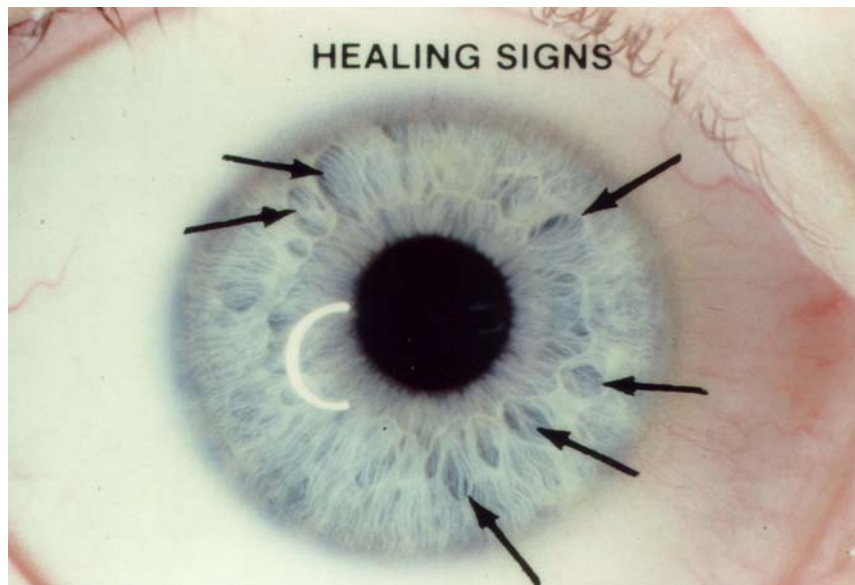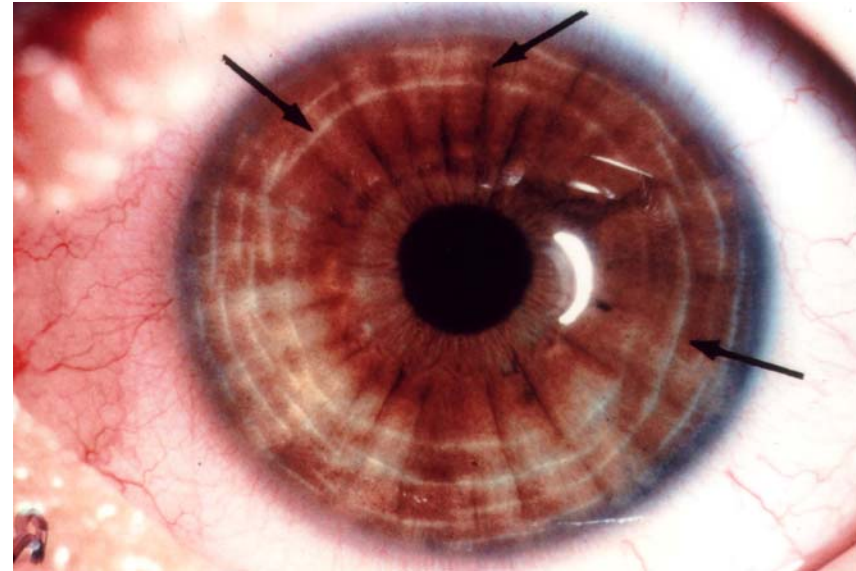


Chronic auto-intoxication with a large scurf rim visible in the right iris and just on the liver area focusing sluggish liver and poor detoxification.

Example of bowel tissue expressed in the heart area.



Very heavy white nerve rings, stress tension, irritability, poor memory, insomnia, fatigue.



Indicates: Tissue regeneration, healing process. Nerve and blood supply are increasing. Healing signs are visible in lesioned areas with white calcium luteum lines after a change occur in the body through detoxification and good nutrition.